

## Severe undernutrition in growing and adult animals

### 15\*. The mouth, jaws and teeth of pigs

BY C. H. TONGE

*Department of Oral Anatomy, University of Newcastle-upon-Tyne*

AND R. A. McCANCE

*Medical Research Council Department of Experimental Medicine,  
University of Cambridge*

(Received 7 December 1964—Accepted 13 April 1965)

Many studies of the effects of nutritional deficiencies on teeth have been reported in the literature and the subject was reviewed by Jenkins (1965). Mineral deprivation and vitamin deficiencies other than those of ascorbic acid affect the development of teeth less than that of other tissues and have not much influence, bad or good, once the dental structures have been fully calcified.

Evidence in man that severe nutritional deficiency may not retard dental development, although it may alter the normal tooth–jaw relationship and give rise to varying degrees of malocclusion, has been provided by Hellman (1923), Boas (1933), Trowell, Davies & Dean (1954) and Stack (1964). The level of feeding has been found to affect the position of the incisors in sheep (Wiener & Purser, 1957).

The investigation now described expands in some detail parts of the ground covered earlier by McCance, Ford & Brown (1961). It concerns particularly animals which have been undernourished for 52 weeks or thereabouts. The controls have been (*a*) animals of the same weight—but much younger, (*b*) animals of the same age—but much larger. Measurements have been made, the gingivae have been examined, the formation, eruption and structure of the temporary and permanent teeth have been recorded after this period of undernutrition, but no rehabilitated animals have been studied. It is hoped to make a later communication about the effects of rehabilitation on dental tissues.

#### EXPERIMENTAL

Twenty-two pigs were used for this investigation and they were reared as previously described (McCance, 1960; Čabak, Gresham & McCance, 1962). The twelve undernourished pigs were killed when they were a year old and weighed between 4.7 and 6.1 kg. Six normal animals were killed at about 4 weeks of age when they weighed 4.8–7.4 kg and four well-nourished pigs were killed when they were 52 weeks old and weighed between 151 and 184 kg. The former acted as the weight or size controls and the latter as the age controls. The jaws were freed from all soft tissues with the exception of the gingivae and palatal mucosa and fixed in a neutralized mixture of

\* Paper no. 14: *Brit. J. Nutr.* (1964), **18**, 613.

commercial (approximately 40%) formaldehyde (10 parts) and 0.9%, w/v, sodium chloride solution (90 parts). Selected measurements were made of the neurocranium, facial skeleton and teeth. The measurements in Table 1 were made between the two points stated in the table according to the diagrams and descriptions of Wilder (1921) and McCance *et al.* (1961). The degree of attrition of individual teeth was recorded together with any visible malocclusion. Radiographs were taken of sagittal sections of the heads, and histological preparations of selected regions were stained by various cellular and connective tissue methods. Some individual teeth were halved, one half prepared as ground sections, the other as decalcified serial sections. Histological preparations of selected regions were stained by haematoxylin and eosin, Mallory's collagen stain, Mallory's phosphotungstic acid-haematoxylin method, Foot's silver impregnation method for collagen tissue, Schiff's reagent in Feulgen's reaction, Shorr's stain (Carleton & Drury, 1957).

## RESULTS

### *Anatomical measurements*

Table 1 (columns *a*, *b* and *c*) gives the mean values, the numbers and the ranges of the body-weights of the animals investigated. It also gives the same information about the facial measurements made on these animals and, for comparison, the measurements made on the humerus of similar animals in a previous investigation (Dickerson & McCance, 1961). The remaining three columns show the mean values for the undernourished and for the age controls expressed as a percentage of those of the weight controls, and the mean values for the age controls expressed as a percentage of those of the undernourished animals. When the measurements can be compared with the figures for single pigs given by McCance *et al.* (1961) the agreements are reasonably close. Although the ratios are not all strictly comparable one with another since the means for the measurements are based on different numbers of pigs on the same treatment, taken in conjunction with the measurements in the first three columns they show in a very clear way some of the differential effects of undernutrition. The comparison of the undernourished animals with the weight controls shows how the measurements were affected by very slow growth to an equal weight; the comparison of the age control with the weight control shows what the dimensions should have been if the animals had never been undernourished. The other comparison, of the age controls with the undernourished animals, indicates approximately how the growth of the latter was impeded by the undernutrition.

Table 1 shows that all the measurements except one, the palate breadth, were larger in the undernourished animals than in the weight controls, which is an expression of the well-known fact that during undernutrition in immature animals bone has a considerable priority of growth over muscle and fat. The measurements, however, were not all increased to the same extent, and on the whole there was more increase in the length and height of the jaw than in its width. This is attributable to the development of the teeth, which have an even greater priority of growth, when the time comes, than bone. The crowns of the deciduous dentition are laid down *in utero*, and the crowns

have attained their normal size before the commencement of undernutrition. Calcification of the crown of the first permanent molar begins just before or after birth. In addition to these teeth, space has to be made in the jaws for the inevitable development of the permanent dentition. Since teeth are normally aligned one behind another along the length of the maxilla and mandible, their development must be accompanied

Table 1. *Mean values, ranges and comparative measurements of the skulls of undernourished pigs and of normal pigs of the same weight and of the same age*

	Mean values and ranges			Comparative measurements		
	(a)	(b)	(c)	$\frac{a \times 100}{b}$	$\frac{c \times 100}{b}$	$\frac{c \times 100}{a}$
	Under-nourished	Weight control	Age control			
Body-weight (kg)	5.4 (9) 4.7-6.1	5.7 (5) 4.8-7.4	168 (4) 151-184	95	2950	3120
Upper facial length (basion-prosthion) (cm)	14.7 (9) 13.0-16.3	10.2 (5) 7.9-11.3	27.9 (4) 26.9-29.9	144	274	190
Lower facial length (basion-gnathion) (cm)	11.5 (9) 10.4-13.0	8.4 (5) 5.8-9.6	21.6 (4) 20.1-23.7	137	258	189
Facial height (nasal tip-interdentale superius) (cm)	2.3 (9) 1.7-2.9	1.7 (5) 1.0-2.1	4.8 (4) 3.5-6.4	135	282	210
Palate length (orale-staphylion) (cm)	8.9 (9) 7.9-10.4	6.7 (5) 5.4-8.4	16.9 (4) 15.5-19.5	133	252	190
Palate breadth (inner borders of sockets of the two upper second molars, endomolaria) (cm)	2.5 (5) 2.2-2.7	2.5 (4) 2.3-2.9	4.0 (2) 3.8-4.2	100	160	160
Mandible, condylar breadth (right-left condyilion laterale) (cm)	7.7 (7) 6.9-8.7	6.1 (3) 5.6-6.7	14.7 (2) 14.3-15.0	127	241	190
Mandible, angular breadth (right-left gonion) (cm)	6.4 (8) 2.2-8.3	5.6 (3) 5.0-6.0	13.4 (2) 13.0-13.8	114	240	210
Mandible, anterior breadth (inner borders of the right-left mental foramina) (cm)	2.1 (6) 1.2-2.7	1.5 (3) 1.1-2.2	3.2 (2) 2.5-3.8	140	213	152
Mandible, length (see McCance, Ford & Brown, 1961) (cm)	12.7 (8) 9.4-14.0	8.4 (5) 7.4-9.9	25.2 (4) 23.5-27.0	150	297	198
Mandible, height of body (interdentale inferius-gnathion) (cm)	3.5 (9) 2.8-4.7	2.5 (5) 2.3-2.7	7.7 (4) 7.4-8.3	140	308	220
Mandible, height of condyle (gonion-highest points of condyle) (cm)	5.4 (9) 5.0-6.2	4.0 (5) 3.8-4.4	13.1 (4) 12.3-14.2	135	328	242
Width of ramus (least width at right angles to height) (cm)	4.6 (9) 3.3-7.4	2.6 (5) 2.4-2.9	6.9 (4) 6.4-7.7	177	265	150
Humerus, length (cm)	9.0	7.9	20.9	114	266	233
Humerus, breadth (cm)	1.6	1.2	3.7	133	308	230

The figures in parentheses are the numbers of animals used.

by growth in length of the jaws. Without any such stimulus to elongate, the humerus only increased in length to about the same extent as the jaw did in a lateral direction. Since function also affects the development and shape of a bone, the increase in the anterior breadth of the mandible and other alterations of shape, visible but not

recorded in Table 1, may be attributed to muscular and glandular development. This matter is being pursued and will be reported upon and discussed more fully in a subsequent paper on rehabilitation.

#### *The palatine ridges and gingivae*

The effect of growth on the lining membrane of the mouth has been little investigated and still less is known about the effect of undernutrition on it. In most species of animal the palate is characterized by transverse ridges or rugae which differ considerably in size and number. They were first studied by Winslow (1753) and more extensive accounts have been published by Linton (1905), Retzius (1906), Ellenberger & Baum (1915) and Schultz (1949). These investigations have indicated that in pigs the number of rugae varies from 20 to 25. In all the animals now studied there was a well-defined incisive papilla in front (Pl. 1*a* and, better, Pl. 1*e*). The ridges were transverse and numbered between 20 and 25, but the exact number was not easy to define because the counting and identification were sometimes difficult round the incisive papilla, and at the junction of the hard and soft palates. There, the terminal ridge was often poorly developed on either side and sometimes represented only by an irregular mid-line elevation. The ridges tended to branch and were sometimes discontinuous, particularly the first or second and the thirteenth to seventeenth ridges, which in normal animals 1 year old lie adjacent to the third premolar and second molar teeth. Neither growth nor undernutrition appeared to affect the numbers, arrangement and relative sizes of the rugae. The only measurements affected by either process appeared to be the actual size of the rugae and the measurable distance between them.

The mucous membranes of the gingivae of the normal animals 4–5 weeks old were immature. The keratin was very thin but formed a complete covering without any signs of parakeratosis. The gingivae of the undernourished animals were more developed. The layer of keratin was thicker and showed evidence of parakeratosis. In the age controls the layer of keratin was dense and thick and the desquamation was of the type to be expected on the surface of a mature epithelium. In the weight controls there was not much evidence of papilla formation, whereas in the age controls the epithelium was much thicker and there was considerable papillary development. In the undernourished animals the epithelium was thin and immature in comparison with a normal animal of the same age, but the papillae were more developed than those of the weight controls.

#### *Dental development*

##### *Clinical and post-mortem findings*

*Well-nourished animals 1 year old.* Pl. 1*a* shows that in the maxilla of these animals (the age controls) the deciduous first and second incisors were present, that the second permanent incisor was erupting at the expected time (12–13 months), and that the third permanent incisor and the canine, which normally begin to erupt at 7–8 months and 10–11 months, respectively, had partly erupted. The first premolar (normal eruption 4–5 months) was present and attrited. The second and third deciduous molars

(normal eruption 4–5 weeks) and the first deciduous molar (normal eruption 7–10 weeks) were all worn down, and the first and second permanent molars had erupted. The first normally erupts at 3–4 months and the second at 8–9 months. There was a normal and well-defined diastema between the third incisor and the canine. In the mandible (Pl. 1*b*) the first and second permanent incisors were erupting normally at 12–13 months. The deciduous incisors were being shed and the remnants of their crowns were quite loose. The third permanent incisor and the permanent canine, which normally appear at 7–8 months and 10–11 months respectively, had erupted. The three deciduous molars in the lower jaw which erupt within the same ranges of time as those in the maxilla (see above) had suffered considerable attrition and had well-worn occlusal surfaces. The first and second permanent molars had erupted (normal times 3–4 and 8–9 months). All the molars, deciduous and permanent, forming the cheek teeth were in a straight line occlusally. The first premolar was absent in some pigs but was present with a well-worn occlusal surface in others. This tooth, which normally erupts at 4–5 months, can be regarded either as a deciduous tooth remaining late or a permanent tooth erupting early. Its presence is not constant.

*Undernourished animals 1 year old.* All the jaws examined were similar as regards the teeth which had erupted and were present, except one from an animal weighing 5.45 kg in which the third permanent incisor was beginning to erupt. There were, however, differences in the degree of attrition and malocclusion. A comparison of the findings with those for the age controls above shows the extent to which the year of undernutrition had interfered with the development of the teeth.

In the mandible illustrated in Pl. 1*c* the three deciduous incisors, deciduous canine and the three deciduous molars were still in place. The first permanent molar had erupted. The teeth were crowded and, if the occlusal surfaces of the two sides are compared, it can be seen that the cheek teeth did not lie in a straight line and showed considerable malocclusion.

Pl. 1*d* shows the maxilla of another animal. The first and second deciduous incisors and canine were present. The first premolar had erupted and was much worn away. The three deciduous molars and the first permanent molar had erupted, but none of the other permanent teeth. There was little space between the incisor, canine and premolar areas. Often the premolar and molar teeth did not lie in a straight line, but Pl. 1*d* illustrates a jaw in which this abnormality was very slight. In spite of these delays and abnormalities in dentition considerable growth and development took place during undernutrition if the state of affairs in the undernourished animals is compared with the findings in other, normal, animals of the same body-weight.

*Well-nourished animals 4 weeks old.* In the maxilla of the weight or size controls (Pl. 1*e*) the first deciduous incisor which has normally erupted by the 4th week, the third deciduous incisor and the deciduous canine, both of which should erupt about the time of birth, were all present. The second deciduous molar was erupting, as it should, at 4–5 weeks of age. The first deciduous molar, which does not usually erupt before the 7th–10th week, had not yet appeared but could easily be felt beneath the surface of the gum. The first premolar (normal age for eruption 4–5 months), the second deciduous incisor (normal age for eruption 3–5 months) and the second

deciduous molar (normal eruption age 4-5 weeks) had not yet erupted but some of them could be felt. There was no evidence of overcrowding.

The teeth in the mandible should have similar eruption dates, and the first and third deciduous incisors, deciduous canine and first and second deciduous molars had erupted on the right (Pl. 1*f*). The first premolar was palpable beneath the surface, and again there was no evidence of overcrowding, and only minor differences between the specimens.

### *Radiological findings*

*Well-nourished age controls.* McCance *et al.* (1961) published X-ray photographs of the jaws of a somewhat older animal, and a comparison of them with the ones now published shows the pattern of dental development at about this age. In both jaws of the animal illustrated in Pl. 2*a* the apices of the roots of the permanent incisors and canines were open, indicating that root formation was still in progress in connexion with the further eruption of the crown. Resorption of the deciduous incisors was incomplete, but could be seen from other photographs to be extensive on their lingual and palatal surfaces. The degree of resorption of the first lower deciduous incisor in one specimen had exposed a part of the pulp in the pathway of the eruption of the succeeding permanent tooth. There was some resorption of the mesial surface of the mesial root of the first premolar in the maxilla near to its apex and also of the adjacent bone area. The distal (lateral) root was less resorbed near the distal surface of the apex but the alveolar bone round it had been greatly resorbed by the expanded crypt containing the second premolar. The lateral surface of the first premolar was in contact with the mesial surface of the first deciduous molar. The mesial roots of the first deciduous molar in the upper jaw were more resorbed than those of the first premolar and so were mesial surfaces of the distal roots; part of the occlusal surface of the second premolar was in contact with them. The apical two-thirds of the roots of the maxillary second deciduous molar had been resorbed to the extent of forming a cavity into which the third premolar fitted. The third deciduous molar in the maxilla had lost almost all its roots and lay directly below the occlusal surface of the third premolar. The first and second permanent maxillary molars had not completed their root formation and the third permanent molar had an extensive crown formation with cusps, but as yet no roots. There was plenty of room for the eruption of this tooth.

The distal root area of the first deciduous molar in the mandible was more resorbed than the mesial and there was still some interradicular bone. The crown of the second premolar in the mandible was well formed and the cervical quarters of the roots were visible. The roots of the second and third deciduous molars in this jaw were extensively resorbed. The roots of the third had almost gone and the occlusal surface had been so worn down that the pulp chamber had been almost exposed. The third and fourth premolar teeth had fully formed crowns and the development of the roots was under way. The first and second permanent molar teeth in the lower jaw had completed their crown formation and showed considerable root development. The apical foramina of the first were almost complete; those of the second, however, were still open.

The third permanent molar lay in the anterior part of the ramus of the mandible; its crown was complete and moving towards a normal position prior to eruption. The roots were not yet visible. As may not be so in man, there always appeared to be adequate room in the lower jaw for the eruption of the premolar and third molar teeth without any malocclusion. There was no evidence of lines of arrested growth in either jaw and the ramus joined the mandible at an angle greater than  $90^\circ$ .

*Undernourished animals.* In both jaws (Pl. 2*b*) there was overcrowding of the permanent dentition; its development was retarded and its eruption delayed. Unlike those in normal animals of the same age, the roots in the premolar and molar areas had scarcely begun to develop. The root apices of the deciduous molars in both jaws were only beginning to be absorbed (in contrast to the appearances in Pl. 2*a*) and there were radiolucent areas and signs of remodelling in the interradicular bone. The developing premolars of the permanent dentition were all less radio-opaque than those in the normal age controls, and their crowns were incomplete. The second permanent molars in both jaws were impacted against the distal aspect of the first permanent molars which had erupted, but still had incomplete roots. There was rarely any radiological evidence of calcification in the third permanent molar. In both jaws and in all specimens, but particularly in the ramus of the mandible, there were multiple 'lines of arrested growth'. These were reported in the mandible by McCance *et al.* (1961) but not illustrated, and they were the subject of special comment in this bone and the scapula by Pratt & McCance (1964) in their study of growth lines in the long bones.

The ramus joined the body of the mandible at an angle rather less than that of the normal age control, but the most obvious anatomical deformation lay at the front of the mandible. Here the angle between the base of the mandible and the line of eruption of the incisor teeth was very much more obtuse than it should have been and the teeth were in fact growing almost horizontally.

*Well-nourished animals 4 weeks old (the weight controls).* Pl. 2*c* shows that in both jaws of the weight controls the three deciduous incisors, deciduous canine, and deciduous molars were all recognizable. The crown of the first permanent molar could be seen in a crypt in the ramus of the mandible. The first and second deciduous incisors, the deciduous canine and the second deciduous molar had erupted. Their roots were forming actively and the supporting bone had a well-defined lamina dura. The first deciduous molar and the second deciduous incisor were erupting. The cusps on the occlusal surface of the third deciduous molar in the mandible were being calcified and were further developed than those of the equivalent tooth in the upper jaw. There was room for eruption and normal occlusion of the deciduous dentition and no evidence to suggest overcrowding of the calcifying first permanent molar tooth. There were no lines of arrested growth. The ramus joined the body of the mandible at an angle considerably greater than  $90^\circ$ , and the line of eruption of the deciduous incisor teeth in both jaws was similar to that observed in the normal animal 1 year old. This angle is about  $45^\circ$ .

*Histological findings*

Since the crowns of the deciduous teeth had been formed *in utero* and had erupted early after birth they were not affected by undernourishment. Attrition of the enamel and dentine with numerous dead tracts and reparative dentine formation were observable in many teeth in both the normal and undernourished animals. There were also a few lamellae and spindles in the enamel. The characteristics of normal enamel and dentine in a third permanent incisor, which was taken from a pig 1 year old and had not suffered attrition, are shown in Pl. 3*a*.

The roots of the deciduous teeth which formed after the period of undernutrition began showed an increase in the incremental-line pattern and areas of subnormal calcification with interglobular dentine. These areas of interglobular dentine were most extensive in the parts estimated to have been formed soon after the onset of the undernutrition. The dentine most recently formed and lying closer to the pulp cavity contained some interglobular dentine, but less of it as a rule. There were generally numerous lines in the dentine whether in the root or crown, indicating periods of arrested growth.

Pl. 3*b* shows a ground section of a first premolar from an undernourished animal, the tooth of the permanent dentition which is not always present. This tooth normally commences to form at 2–4 weeks of age and erupts at 4–5 months. The dentine in it therefore would have begun to form shortly before the impact of undernutrition disorganized the metabolism of the animal. The plate shows large areas of interglobular dentine lying adjacent to a seemingly normal region.

All the calcified tissues were affected by the undernourishment. Sections stained by the periodic acid–Schiff reaction showed that the cementum was poorly calcified, and bundle bone formation and periodontal membrane fibre re-attachment were observed. Nevertheless, there was some growth of primary and secondary cementum in the undernourished animals and also repair of cementum that had been absorbed. In some of the decalcified sections there was often more predentine to be seen than in normal animals but this was not a constant feature.

Pl. 3*c*, which shows a ground section of a permanent canine taken from one of the undernourished pigs, shows areas in the enamel which were incompletely calcified, irregular striae of Retzius (1837) and the presence of lamellae which are regarded as analogous to the lines of arrested growth found in bones. The greatest departure from normality was found in the region nearest to the amelo-dentinal junction. The normal Hunter–Schreger bands were always visible, and signs of abnormal calcification were frequently found in the enamel over both the cusps and cervical regions of the teeth. In the decalcified preparations the alternating arrangement of the enamel rods in the Hunter–Schreger bands was observable both in teeth which had erupted and in those which had not.

Pl. 3*d* shows some of the abnormalities to which references have already been made, and others not yet described. It is of a ground section of part of the mesial root of the first mandibular molar of the permanent dentition in an undernourished animal 52 weeks old. Similar irregular folding of the dentine was commonly found in root



tissues which had developed during the period of undernutrition. The incremental lines or 'lines of arrested growth' are very conspicuous in this section. The irregularity was confined to the surface of the dentine, the cellular cementum filling in the gap and making a smooth external surface.

#### DISCUSSION

The formation and eruption of the teeth are merely aspects of growth and must be influenced, if only to a relatively small extent, by anything which disturbs it. The earlier work of McCance *et al.* (1961) traced the effects of undernutrition from an early stage of suckling on the skull, jaws and teeth of a series of animals killed at ages which varied from 13 to 64 weeks. The study now presented has extended the investigation in various directions, particularly towards oral anatomy and dental histology, but it has been based upon the examination of twelve pigs all undernourished for the same length of time, and compared with normal pigs of the same age and others of the same weight. The findings show that the teeth were affected less than many of the other tissues, and only those parts of the teeth which were being formed during the period of undernutrition appeared to be affected by it. However, the continuous, if delayed, morphological and histological differentiation of the roots of the deciduous teeth and of the crowns and roots of the permanent teeth indicated that there was co-ordinated cellular activity all the time. There was, for example, no evidence of any failure of the ameloblasts to differentiate, which shows incidentally that there was no shortage of vitamin A (Wolbach & Bessey, 1942), and this is what one would have expected from the previous work (McCance, 1960).

Significant facts which have been brought out are that the degree of undernutrition to which these pigs were subjected (*a*) altered the shape of the mandible and the line of eruption of the incisor teeth, (*b*) retarded the growth and eruption and may have reduced the size of the permanent dentition, (*c*) delayed the absorption of the deciduous dentition, (*d*) produced malocclusion of the teeth, (*e*) created a discrepancy between the size of the teeth and the space available for them in the jaw, (*f*) interfered with the development of the enamel, dentine and cementum, (*g*) allowed the teeth and their surroundings to undergo repair, to move and react to stresses by alterations in the cementum, alveolar bone and periodontal membrane.

No surveys of the progress of dental development in relation to age have been made for pigs which are as extensive as those that are available for man. The results of Sisson & Grossman (1953) and McCance *et al.* (1961) are supported by the study now reported. Silver (1963) has made the point that dental age and bone age in farm animals (including the pig) depend upon the extent to which selection, breeding and domestication may have hastened the rates of growth and the attainment of maturity. Brauer & Bahador (1942), Cattell (1928), Logan & Kronfeld (1933) and others have reported extensively on the variations found in the ages at which eruption takes place in man, on the fact that retardation is commoner than acceleration, the significance of nutritional deficiencies, and the mechanism of tooth movement.

It is known that deciduous teeth may be retained if the permanent successors fail

to form (Aisenberg, 1941). In our own work on pigs the permanent teeth were slow to develop and the deciduous teeth were retained and their crowns worn away, but not more so than the crowns of teeth of normal animals of a similar age. The first premolars and the first molars which erupted during the time of the experiment were as much worn down as those in normal animals of the same age, although they had not taken part in chewing so much food and had been functional for a shorter time.

The malocclusion and crowding of the teeth in the jaws was due not only to insufficient cranial and facial growth, but also to the reduced facial height, palate length and palate width and to the small size of the mandibular ramus. This reduction in the size of the jaw was not accompanied by any reduction in the size of the crowns of the deciduous teeth, but there may have been some restriction in the size of their roots. Some of the premolar teeth, particularly the second and the fourth, were smaller in the three specimens which were examined than in the normal ones, but the first premolar in all specimens in which it was present was of normal size. McCance *et al.* (1961) found a considerable reduction in the size of the third permanent molar in a rehabilitated animal, but changes in the size of teeth should not be regarded as proven and inevitable effects of undernutrition until more material has been examined. The important point seems to be that they are small relative to the effects of undernutrition of this severity on the jaw and other tissues.

The incremental lines in bone described in the pig's mandible and in other bones by Harris (1933, 1939) are similar in character to the incremental lines seen in dentine and cementum and enamel, so far as their significance in relation to periods of retardation in growth is concerned. The formation of interglobular dentine, accentuated lines of growth and an increase in the area of predentine may all be associated with a deficiency of vitamin D (Kronfeld & Barker, 1932; Mellanby, 1929, 1930; Weinmann & Schour, 1945) but can certainly appear when the supply of vitamin D is adequate as it was in these animals. In the experiments described in this paper the greatest degree of disturbance accompanied the onset of the undernourishment.

The increase in the area of predentine seen in several specimens indicates that there was a delay in the rate of calcification (Gaunt & Irving, 1940-1). The results now obtained support the conception that there are 'priorities' of growth among the skeletal and soft tissues of the body (Hammond, 1950). Clarke & Smith (1935) showed that teeth had some degree of priority over bone in a mineral deficiency, and the same appears to be true when the deficiency is a much more general one.

#### SUMMARY

1. Pigs were held by undernutrition at weights of 5-6 kg till they were a year old.
2. Measurements and histological studies were made of their jaws and teeth and compared with those in animals of the same age and of the same weight.
3. Undernutrition: (a) altered the shape and anatomical relationships of the jaws; (b) retarded the normal growth of the gingivae and palatine ridges; (c) delayed the development of the teeth less than that of the jaws and resulted in overcrowding, displacement and malocclusion; (d) prolonged the retention of the milk teeth;

(e) altered the structure of both the enamel and dentine and probably reduced the size of teeth which were formed during the period of undernutrition, and also (f) altered the X-ray appearances and the structure of the maxilla and mandible and produced multiple 'lines of arrested growth'.

One of us (C.H.T.) would like to acknowledge the provision of a grant from the Medical Research Council enabling this work to be carried out and also the technical assistance of W. Kerss and D. Reid in preparing the sections, and the secretarial help of Miss V. Hutton. We have appreciated the help of Mr P. John in preparing the skulls for photography and radiography. Mr L. A. R. Luff was responsible for some of the photography and the radiographs were the work of Mr J. A. F. Fozzard of the Anatomy School, University of Cambridge. The authors are very grateful to Terry Cowen for the never-failing interest and care which he has bestowed on these animals and without whom there might not have been any.

## REFERENCES

- Aisenberg, M. S. (1941). *Amer. J. Orthodont.* **27**, 179.  
 Boas, F. (1933). *Hum. Biol.* **5**, 429.  
 Brauer, J. C. & Bahador, M. A. (1942). *J. Amer. dent. Labs Ass.* **29**, 1373.  
 Čabak, V., Gresham, G. A. & McCance, R. A. (1962). *Brit. J. Nutr.* **16**, 635.  
 Carleton, H. M. & Drury, R. A. B. (1957). *Histological Technique*, 3rd ed. Oxford: Oxford University Press.  
 Cattell, P. (1928). *J. dent. Res.* **8**, 279.  
 Clarke, M. F. & Smith, A. H. (1935). *Amer. J. Physiol.* **112**, 286.  
 Dickerson, J. W. T. & McCance, R. A. (1961). *Brit. J. Nutr.* **15**, 567.  
 Ellenberger, W. & Baum, H. (1915). *Handbuch der vergleichenden Anatomie der Haustiere*, 14th ed. Berlin: Julius Springer.  
 Gaunt, W. E. & Irving, J. T. (1940-1). *J. Physiol.* **99**, 18.  
 Hammond, J. (1950). *Proc. roy. Soc. B*, **137**, 452.  
 Harris, H. A. (1933). *Bone Growth in Health and Disease*, p. 6. London: Oxford University Press.  
 Harris, H. A. (1939). *Nature, Lond.*, **144**, 552.  
 Hellman, M. (1923). *Dent. Cosmos*, **65**, 34.  
 Jenkins, G. N. (1965). *The Physiology of the Mouth*, 3rd ed. Oxford: Blackwell Scientific Publications.  
 Kronfeld, R. & Barker, J. F. (1932). *J. Amer. dent. Labs Ass.* **19**, 105.  
 Linton, R. G. (1905). *Vet. J.* **12**, 220.  
 Logan, W. H. G. & Kronfeld, R. (1933). *J. Amer. dent. Labs Ass.* **20**, 379.  
 McCance, R. A. (1960). *Brit. J. Nutr.* **14**, 59.  
 McCance, R. A., Ford, E. H. R. & Brown, W. A. B. (1961). *Brit. J. Nutr.* **15**, 213.  
 Mellanby, M. (1929). *Spec. Rep. Ser. med. Res. Coun., Lond.*, no. 140.  
 Mellanby, M. (1930). *Spec. Rep. Ser. med. Res. Coun., Lond.*, no. 153.  
 Pratt, C. W. M. & McCance, R. A. (1964). *Brit. J. Nutr.* **18**, 393.  
 Retzius, A. (1837). *Arch. Anat. Physiol.* p. 486.  
 Retzius, G. (1906). *Biol. Untersuch. N.F.* **13**, 117.  
 Schultz, A. H. (1949). *Contr. Embryol. Carneg. Instn.* **33**, 43.  
 Silver, I. A. (1963). In *Science and Archaeology*, p. 250. [D. Brothwell and E. Higgs, editors.] London: Thames and Hudson.  
 Sisson, S. & Grossman, J. D. (1953). *The Anatomy of the Domestic Animals*, 4th ed. Philadelphia and London: W. B. Saunders Co.  
 Stack, M. V. (1964). *Biologia neonat.* **6**, 197.  
 Trowell, H. C., Davies, J. N. P. & Dean, R. F. A. (1954). *Kwashiorkor*. London: Arnold and Co.  
 Weinmann, J. P. & Schour, I. (1945). *Amer. J. Path.* **21**, 821.  
 Wiener, G. & Purser, A. F. (1957). *J. agric. Sci.* **49**, 51.  
 Wilder, H. H. (1921). *A Laboratory Manual of Anthropometry*. Philadelphia, Pa: Blackiston's Son & Co. Inc.; London: Pitmans.  
 Winslow, J. B. (1753). *Expositio anatomica structuræ corporis humani*. Francof et Lipsiae.  
 Wolbach, S. B. & Bessey, O. A. (1942). *Physiol. Rev.* **22**, 233.

## EXPLANATION OF PLATES

## PLATE 1

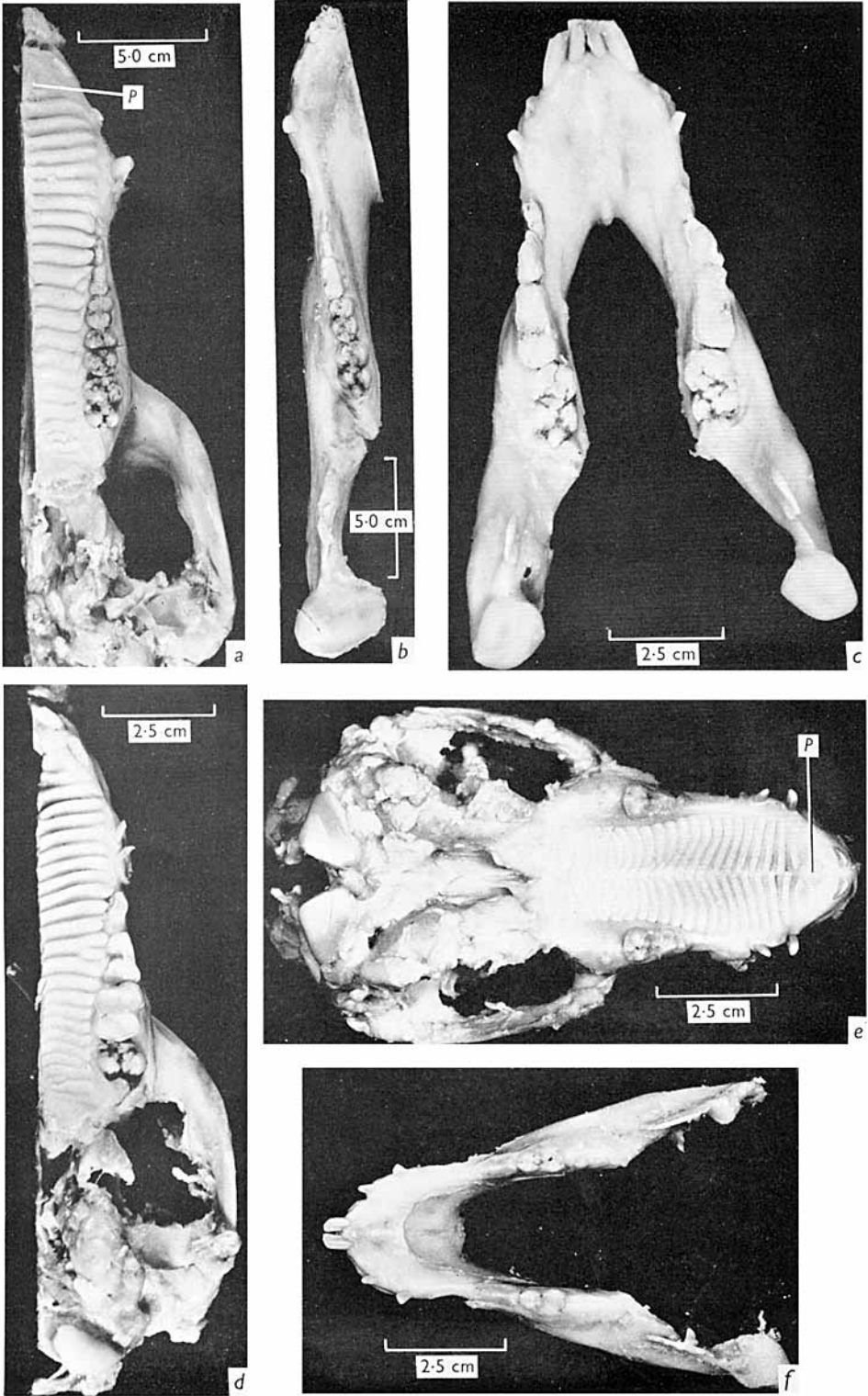
- (a) Left side of the maxilla of a well-nourished pig aged 1 year. Note the incisive papilla *P*, the rugae and the straight occlusal line of the deciduous and permanent molars.
- (b) Left side of the mandible of the same pig.
- (c) The mandible of an undernourished pig aged 1 year weighing 5.4 kg. The third permanent incisor is starting to erupt. The line of the molars is irregular.
- (d) Left side of the maxilla of an animal undernourished for 1 year. Weight 5 kg. Note that the line of the molars is somewhat irregular.
- (e) The maxilla of a normal pig aged about 4 weeks, weight 5 kg. Note the incisive papilla *P* (central and just anterior to the rugae).
- (f) The mandible of another pig of about the same age, weight 5.5 kg.

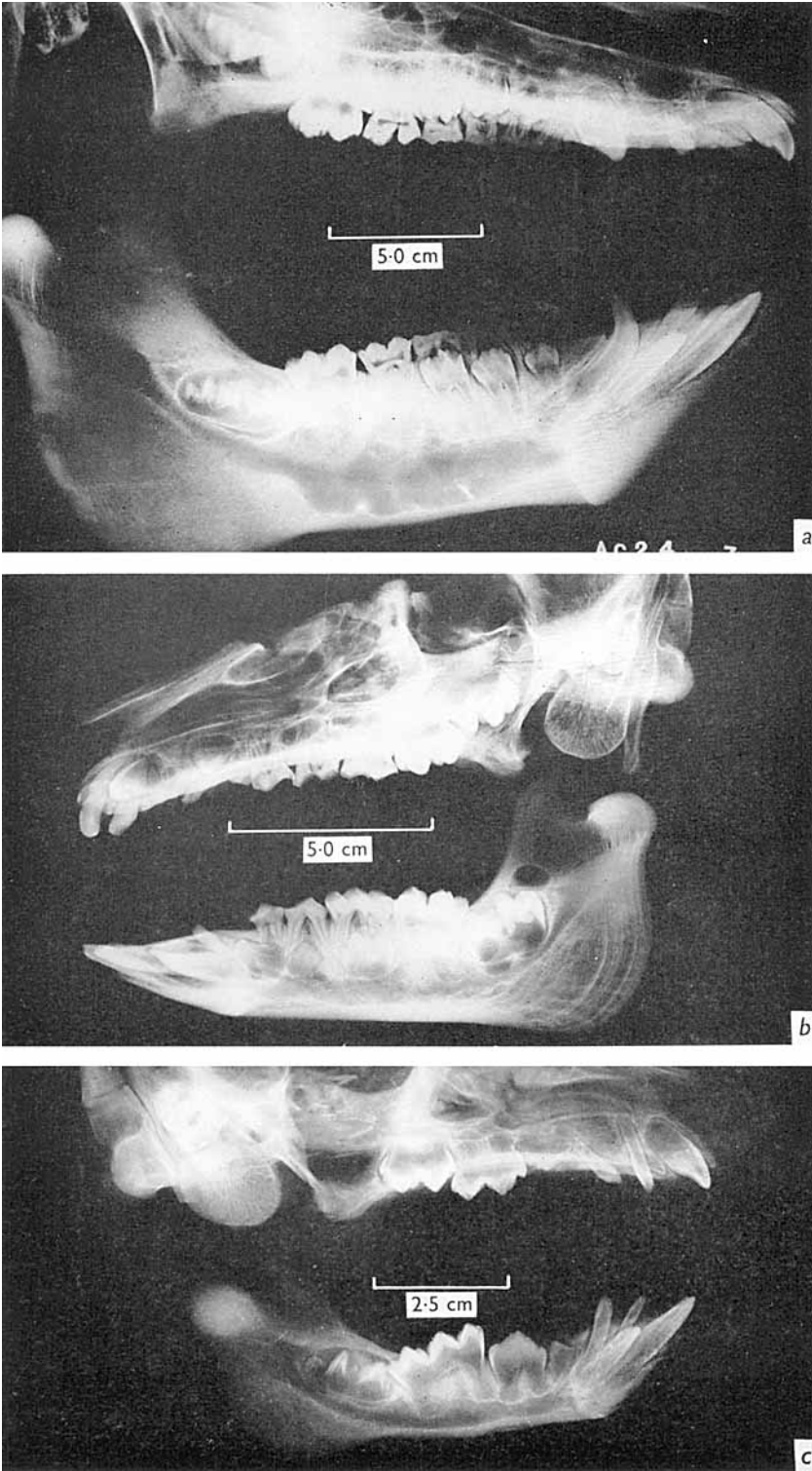
## PLATE 2

- (a) X-ray photographs of the upper and lower jaws of a well-nourished pig 1 year old. The second, third and fourth premolars with well-developed roots are replacing the deciduous molars whose roots have been almost entirely resorbed. Note the line of the incisor teeth relative to the base of the mandible.
- (b) X-ray photographs of the jaws of an undernourished pig 1 year old. The deciduous molars are still *in situ*, with roots not yet resorbed, the premolars have not yet formed their roots or begun to erupt. Compare the anterior angle of the mandible and line of the incisor teeth with that of those in Pl. 2a and c. Note the lines of arrested growth in the ramus of the mandible.
- (c) X-rays of the jaws of a well-nourished pig aged 4 weeks and weighing about 5 kg. Note the deciduous molars and first permanent molar tooth in the lower jaw and the line of eruption of the incisor teeth relative to the base of the mandible.


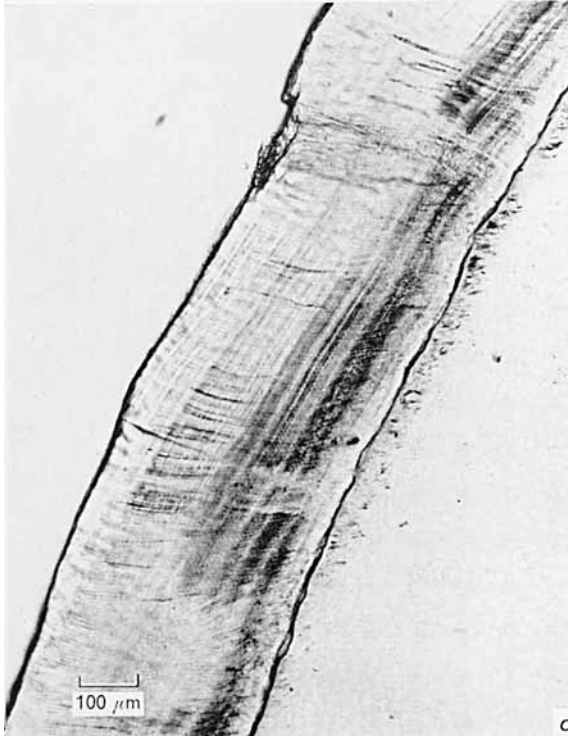
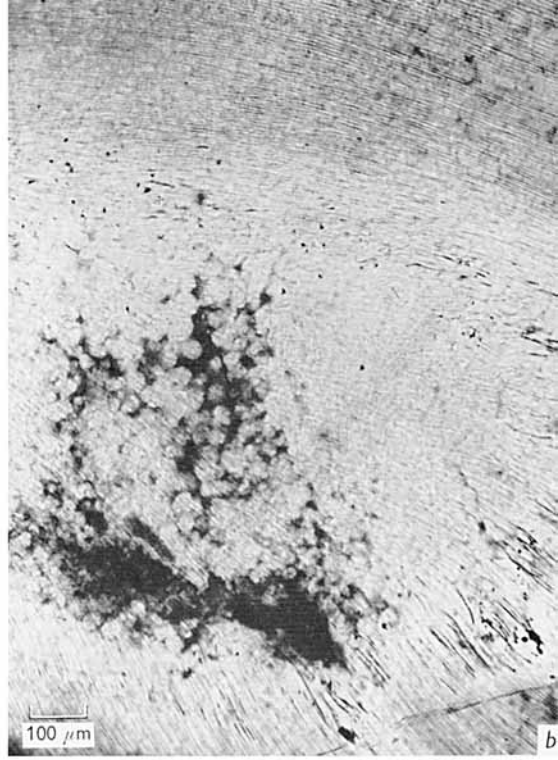

## PLATE 3

- (a) A ground section of the third permanent incisor of a well-nourished pig 1 year old. Note the regular spacing of the incremental lines in the enamel, the regularity of the amelo-dentinal junction and the normal tubules in the dentine.
- (b) A grossly abnormal area of interglobular dentine visible in a ground section of the first premolar tooth of an undernourished pig 1 year old weighing about 5 kg. The dentine in other parts of the section is relatively normal.
- (c) Abnormal calcification of the enamel in a ground section of a permanent canine from another undernourished pig 1 year old (see p. 368).
- (d) A ground section of part of the mesial root of the first permanent mandibular molar of a pig undernourished for 52 weeks. The surface of the dentine is folded and most irregular and the lines of arrested growth are very conspicuous.





C. H. TONGE AND R. A. McCANCE



C. H. TONGE AND R. A. McCANCE