

Endovascular Therapy of a Large Vertebral Artery Aneurysm using Stent and Coils

Stephen P. Lownie, David M. Pelz, Allan J. Fox

ABSTRACT: Background: Endovascular therapy is becoming an increasingly popular treatment for cerebral aneurysms. Total angiographic occlusion of small-necked aneurysms (<4 mm) can be obtained in a high percentage of cases. The endovascular treatment of wide-necked or fusiform aneurysms remains a challenge with complete angiographic occlusion reported in <15% of cases. **Case Report:** We describe the combined use of a flexible coronary stent and platinum coils to treat a wide-necked aneurysm of the distal left vertebral artery, in a patient with Grade IV subarachnoid hemorrhage. **Results:** The procedure was technically successful as the parent artery was protected by the stent while coils were deposited in the aneurysm lumen. Although angiographic aneurysm occlusion was incomplete, the dome was packed with coils. No further hemorrhage has occurred. **Conclusion:** Combined endovascular stent and coil therapy is a promising technique for the treatment of wide-necked cerebral aneurysms.

RÉSUMÉ: Traitement endovasculaire d'un gros anévrisme de l'artère vertébrale au moyen d'un stent et de serpentins. Introduction: Le traitement endovasculaire de l'anévrisme cérébral devient de plus en plus populaire. L'occlusion angiographique totale des anévrismes à col étroit (4mm) peut être réalisée dans une grande proportion des cas. Le traitement endovasculaire des anévrismes à col large ou des anévrismes fusiformes demeure un défi, une occlusion angiographique complète étant rapportée dans <15% des cas. **Cas clinique:** Nous décrivons l'utilisation combinée d'un stent coronarien flexible et de serpentins de platine pour traiter un anévrisme à col large de la portion distale de l'artère vertébrale gauche chez un patient présentant une hémorragie sous-arachnoïdienne de grade IV. **Résultats:** L'intervention a été un succès technique, l'artère mère étant protégée par le stent alors que les serpentins étaient placés dans la lumière de l'anévrisme. Bien que l'occlusion angiographique de l'anévrisme était incomplète, le dôme en était rempli de serpentins. Aucun saignement ne s'est produit depuis l'intervention. **Conclusion:** L'utilisation combinée d'un stent et de serpentins est une technique prometteuse pour le traitement des anévrismes cérébraux à col large.

Can. J. Neurol. Sci. 2000; 27: 162-165

Wide-necked intracranial aneurysms are challenging lesions to treat.¹ Surgical clipping may be difficult or impossible if a true neck is not present. Endovascular therapy of these lesions has been limited to proximal balloon occlusion if adequate collateral circulation exists^{2,3} and, more recently the "remodelling" technique⁴ which involves platinum coil deposition in the aneurysm lumen with temporary balloon occlusion of the parent vessel to prevent egress of the coils. In this case report, we describe the treatment of a wide-necked aneurysm of the distal left vertebral artery using a flexible coronary stent to bridge the wide neck and allow safe placement of platinum coils through the interstices of the stent to occlude the aneurysm lumen.

CASE REPORT

A 64-year-old male presented with a sudden severe headache three weeks prior to admission. He was treated for presumed tension headache but then experienced another severe headache with decreased level of

consciousness. A CT scan (Figure 1) showed a large acute subarachnoid and intraventricular hemorrhage with hydrocephalus. He was intubated and sent to our institution for further investigation and management.

On admission to the intensive care unit, the patient was unconscious with no spontaneous movements, eye opening or speech. He did localize to moderately painful stimuli bilaterally and could move all four limbs. His pupils were 2 mm and sluggishly reactive, corneal reflexes were intact and plantar reflexes were downgoing. He was assessed as Hunt and Hess Grade IV.

Cerebral angiography demonstrated a large, wide-necked aneurysm

From the Department of Diagnostic Radiology; and the Department of Clinical Neurological Sciences, The University of Western, London, Ontario, Canada.

RECEIVED SEPTEMBER 17, 1999. ACCEPTED IN FINAL FORM DECEMBER 15, 1999.

Reprint requests to: David M. Pelz, Department of Diagnostic Radiology, London Health Sciences Centre, 339 Windermere Road, London, Ontario N6A 5A5 Canada.

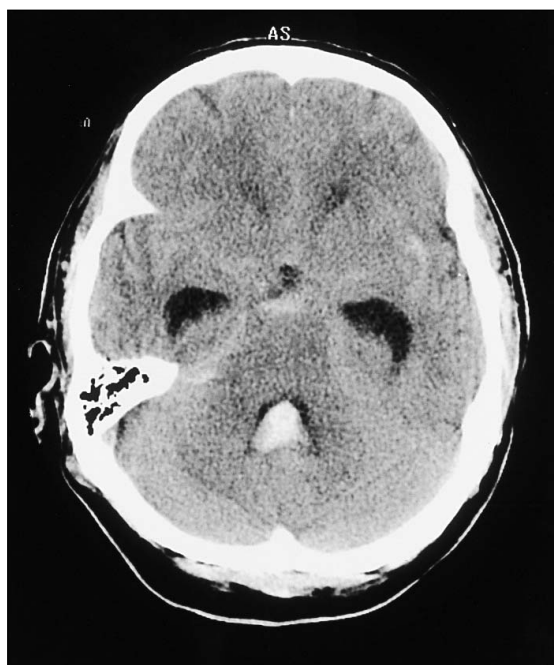

Figure 1: A noncontrast CT head scan shows acute subarachnoid and intraventricular hemorrhage with early hydrocephalus.

of the distal left vertebral artery (Figure 2). The neck measured at least 8-10 mm and the dome diameter was approximately 1.2 cm. The left posterior inferior cerebellar artery (PICA) originated more proximally from the vertebral artery. The right vertebral artery was small and ended in the right PICA. There was no spontaneous filling of the posterior communicating arteries and compression views were not done. There was no significant vasospasm and no other aneurysms were identified. A ventricular drain was placed and the patient improved over the next few days to Hunt and Hess Grade III. His level of consciousness improved and he was intermittently moving his arms and legs spontaneously and to command. He would open his eyes to command yet he continued to only withdraw bilaterally to painful stimuli. Due to the poor clinical

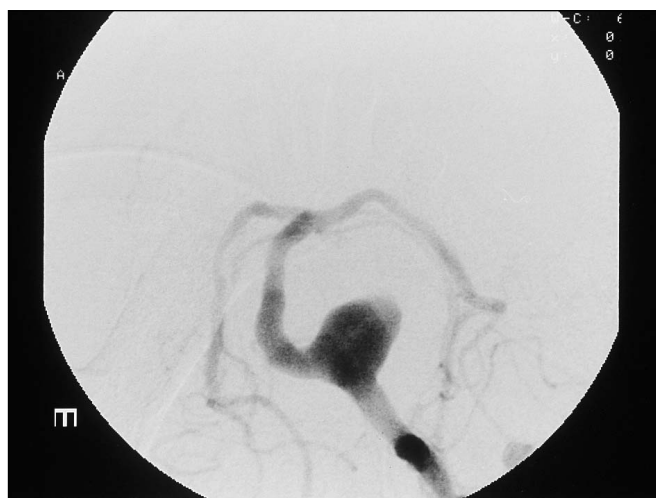

Figure 2: Left vertebral arteriogram, basal oblique projection (same projection in all figures), shows a large, wide-necked aneurysm of the distal left vertebral artery.

grade, it was decided to attempt endovascular treatment. This was performed five days after the hemorrhage.

The patient was placed under general anaesthetic in the neuroangiography suite. A 9 French sheath was placed in the left femoral artery using Seldinger technique. The left vertebral artery was then selectively catheterized using a 9 French Shuttle introducing catheter (Cook, Bloomington IN). A 0.014 guidewire was then advanced through the introducing catheter into the vertebral, basilar and left posterior cerebral arteries. An AVE coronary artery stent (Medtronic, Mississauga ON), 5 mm diameter, 3 cm length was then placed across the base of the aneurysm. Great care was taken to ensure adequate stent purchase on either side of the aneurysm base, and the stent was then deployed (Figure 3).

A two-tip marker Tracker 10 microcatheter (Target/Boston Scientific, Fremont CA) was then advanced into the distal left vertebral artery. The microcatheter was navigated through the interstices of the stent into the aneurysm lumen (Figure 4). When satisfactory catheter position was achieved, seven Guglielmi Detachable Coils (GDC) were deposited

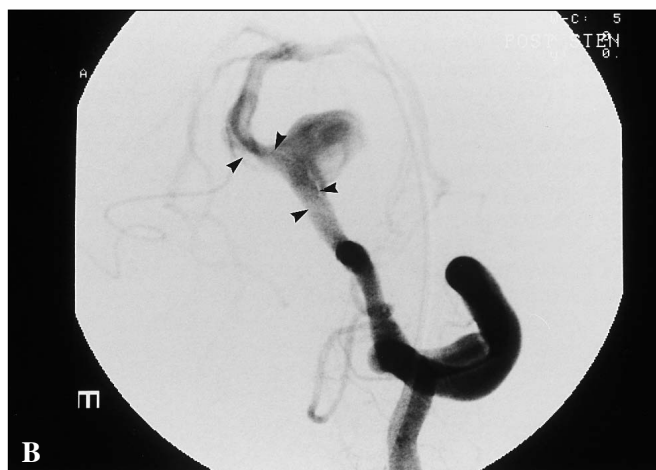
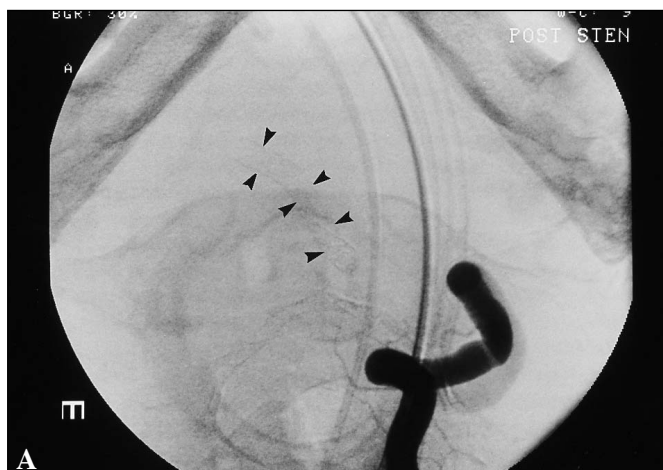


Figure 3: Left vertebral arteriogram. The stent is seen after deployment across the neck of the aneurysm (arrowheads), before (A) and after (B) contrast opacification.

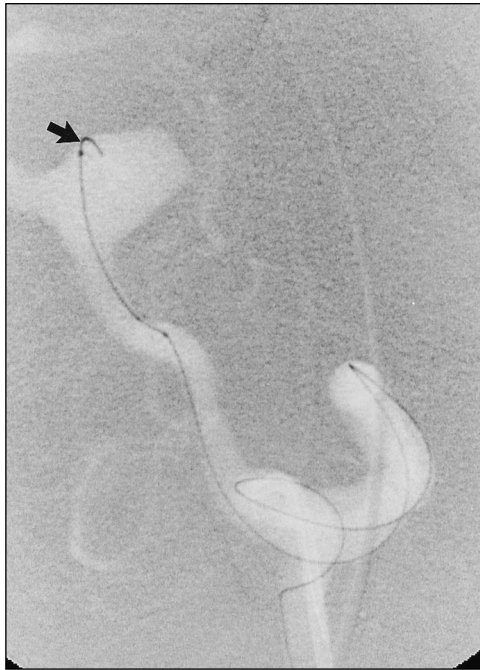

Figure 4: Digital road-map left vertebral arteriogram showing the microcatheter and guidewire in the aneurysm lumen after passage through the interstices of the stent (arrow).

within the aneurysm lumen (Figure 5). There was some resistance during deposition of the last two coils, and the last one detached prematurely during attempted withdrawal. This was likely due to damage incurred at the coil wire junction during introduction rather than by stent traction during coil withdrawal. An attempt to retrieve this coil was unsuccessful and it was left in situ, with the proximal end in the aortic arch, and no coiling observed in the vertebral artery. In our experience with damaged minicatheters and coils left in the aorta, clinical complications have been rare.

The postembolization angiogram showed continued filling of the aneurysm with stasis of contrast in the dome (Figure 6). The patient

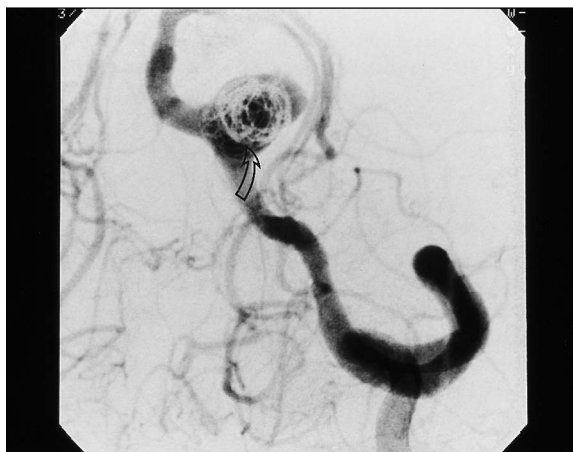

Figure 5A: Left vertebral arteriogram. Numerous GDC coils are seen in the aneurysm. The coils surround and abut on the stent in the bulbous neck of the aneurysm (arrow).

tolerated the procedure well and afterwards he was spontaneously opening his eyes and following commands. He was maintained on antiplatelet medication (Aspirin 350 mg once a day). His level of consciousness gradually improved but his postoperative course was complicated by the development of hydrocephalus, meningitis, pneumonia, and a subdural hematoma after a fall. He had difficulties with swallowing and an unusual hypophonia. Postoperative MRI examinations showed no evidence for new infarction although the brainstem was partially obscured by metal artefact. Postoperative angiography was not performed due to the patient's medical complications, but ultrasound showed continued patency of the left vertebral artery. On discharge to his home hospital for rehabilitation one month after the procedure, he was oriented to name and place, following commands and moving all extremities but he did have residual proximal limb weakness and hypophonia. The mechanism of these deficits was uncertain but was thought to be related to brainstem injury at the time of hemorrhage rather than by perforator occlusion by the stent and coils.

DISCUSSION

GDC coiling has become a popular alternative to surgery for the treatment of cerebral aneurysms.^{5,6} Complete angiographic occlusion can be obtained in up to 85% of aneurysms with necks <4 mm in diameter, but <15% in aneurysms with wider necks.⁷

Difficulties in the coiling of large aneurysms occur at the base if the neck is wider than the dome height.⁷ It is very difficult to prevent egress of coils into the parent artery in these situations, with attendant risks of thrombus formation, distal emboli or vessel occlusion. The "remodelling technique" has been described by Moret et al⁴ to address these problems. One or two nondetachable balloon catheters are placed at the base of a wide-necked aneurysm. A minicatheter is introduced into the aneurysm lumen for coil deployment, and the balloon is temporarily inflated as the coils approach the neck to prevent them from encroaching on the parent vessel, and to mold them to the aneurysm contour. This technique therefore involves multiple catheters and temporary vessel occlusion.

The use of stents in the treatment of experimental aneurysms has been demonstrated by several authors.^{8,9} Stents and coils were used in these reports to successfully treat fusiform aneurysms in pigs. Covered stents have also been used to treat

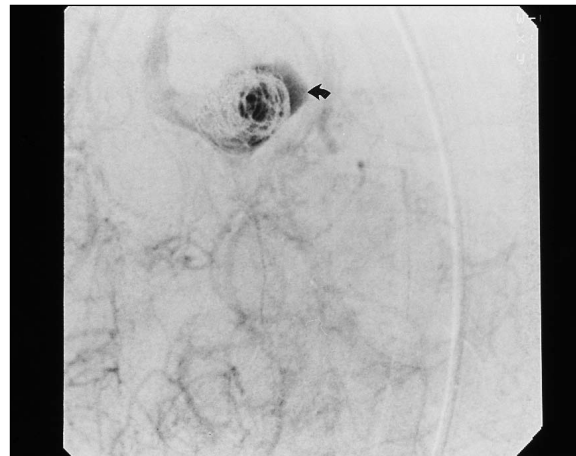


Figure 5B: Left vertebral arteriogram. Stasis of contrast is seen in the dome (arrow).

experimentally created arteriovenous fistulae.¹⁰ In humans, vein-covered stents have been used to repair a traumatic cervical carotid pseudoaneurysm.¹¹

In our case, surgical options were limited due to the very wide neck of the posterior circulation aneurysm. Proximal balloon occlusion of the left vertebral artery would have been hazardous due to the small right vertebral artery which ended in PICA and the uncertain status of the posterior communicating arteries.

To our knowledge, this is the first use of a stent and platinum coils to treat a wide-necked intracranial aneurysm in Canada. Higashida et al¹² have reported the use of this technique to treat an acutely ruptured fusiform aneurysm of the basilar artery with a subtotal angiographic occlusion and a good clinical result. They used an articulated Palmaz-Schatz coronary stent (Johnson and Johnson, Warren NJ) and GDC coils. In our case, we chose a more flexible coronary artery stent which easily traversed the curves of the vertebral artery and permitted passage of a Tracker 10 minicatheter through the interstices for GDC coil deployment. It was also hoped that the interstices of the stent would permit continued perfusion of distal vertebral artery perforating vessels.

Lanzino et al¹³ have recently reported on their series of eight patients treated with a combined stent and coil approach. In this group, which included both anterior and posterior circulation aneurysms, they observed over 90% thrombosis of all lesions and no periprocedure complications.

Although the angiographic occlusion was initially incomplete, it was hoped that further thrombosis would occur on follow-up angiograms which may be performed in the future. There has been no further hemorrhage at four months follow-up and the patient continues to improve slowly in rehabilitation.

The use of stents for cerebral aneurysm treatment may be limited by the proximity of small perforating vessels to the neck of the aneurysm which may be compromised by the stent. The added thrombogenic potential of stents and the possible development of neointimal hyperplasia with parent vessel stenosis may be further limitations of this treatment. There is a theoretical risk of coil damage during passage through the interstices of the stent, resulting in difficulties with placement and detachment.

Stents and coils offer unique opportunities to treat difficult intracerebral aneurysms. Technologies are evolving rapidly and

a possible future modification includes the use of covered stents to occlude the wide necks of large aneurysms. The endovascular treatment of fusiform aneurysms without defined necks remains problematic.

REFERENCES

1. Drake CG, Peerless SJ, Hernesniemi JA. *Surgery of Vertebrobasilar Aneurysms*, New York: Springer, 1996.
2. Fox AJ, Vinuela F, Pelz DM, et al. Use of detachable balloons for proximal artery occlusion in the treatment of unclippable cerebral aneurysms. *J Neurosurg* 1987;66:40-46.
3. Higashida RT, Halbach VV, Dowd CF, et al. Interventional neurovascular treatment for giant aneurysms of the posterior circulation. *J Surg Cereb Stroke* 1993;21:401-406.
4. Moret J, Cognard C, Weill A, Castaing L, Rey A. The "Remodelling Technique" in the treatment of wide-necked intracranial aneurysms. *Intervent Neuroradiol* 1997;3:21-35.
5. Vinuela F, Duckwiler G, Mawad M, Guglielmi detachable coil embolization of acute intracranial aneurysm: perioperative and clinical outcome in 403 patients. *J Neurosurg* 1997;86:475-482.
6. Cognard C, Weill A, Castaing L, Rey A, Moret J. Intracranial berry aneurysms: angiographic and clinical results after endovascular treatment. *Radiology* 1998;206:499-510.
7. Zubillaga AF, Guglielmi G, Vinuela F, Duckwiler GR. Endovascular occlusion of intracranial aneurysms with electrically detachable coils: correlation of aneurysm neck size and treatment results. *Am J Neuroradiol* 1994;15:815-820.
8. Massoud TF, Turjman F, Ji C et al. Endovascular treatment of fusiform aneurysms with stents and coils: technical feasibility in a swine model. *Am J Neuroradiol* 1995;16:1953-1963.
9. Szikora I, Guterman LR, Wells KM, et al. Combined use of stents and coils to treat experimental wide-necked carotid aneurysms: preliminary results. *Am J Neuroradiol* 1994;15:1091-1102.
10. Geremia G, Bakon M, Brennecke L, et al. Experimental arteriovenous fistulas: treatment with silicone-covered metallic stents. *Am J Neuroradiol* 1997;18:271-277.
11. Marotta TR, Butler C, Taylor D, Morris C, Zwimpfer T. Autologous vein-covered stent repair of a cervical internal carotid artery pseudoaneurysm: technical case report. *Neurosurgery* 1998;42:408-413.
12. Higashida RT, Smith W, Gress D, et al. Intravascular stent and endovascular coil placement for a ruptured fusiform aneurysm of the basilar artery. *J Neurosurg* 1997;87:944-949.
13. Lanzino G, Wahkloo AK, Fessler RD, et al. Efficacy and current limitations of intravascular stents for intracranial internal carotid, vertebral, and basilar artery aneurysms. *J Neurosurg* 1999;91(4):538-546.