

Stabbed

Michael Wansbrough, MD, MSc (Epi), DTM&H, DLSHTM

A 16-year-old male was brought to the emergency department by ambulance 20 minutes after being stabbed in the left chest. He complained of chest pain and mild shortness of breath. The stabbing took place after a heated soccer match, when a disgruntled opponent held him down for another player to stab. The patient grabbed the stabbing hand of the assailant and pulled the knife out of his chest. He did not know the length of the blade. A recent immigrant, he had never received tetanus immunization. He had no other medical problems.

Examination revealed an alert, athletic male, covered in blood and in obvious pain. His respiratory rate was 20 breaths/min, blood pressure 130/85 mm Hg in both arms, heart rate 115 beats/min, and his oxygen saturation was 100% on room air. There was a 3-cm horizontal entrance wound in his left third intercostal space at the mid-clavicular line, and he was tender above the clavicle. Breath sounds were symmetrical. The trachea was midline, and there was no subcutaneous emphysema. Heart sounds were normal, radial pulses were present and his abdomen was benign.

Crystalloid was delivered via two large-bore IVs, and blood was typed and cross-matched. Morphine, tetanus toxoid and tetanus immunoglobulin were administered. Upright chest x-ray (Fig. 1) revealed a normal mediastinum and no apparent pneumothorax. Additional lateral and expiratory films were unremarkable, and the ECG was within normal limits.

At this point, the best course of action is:

- A. Place left-sided chest tube assuming missed hemothorax
- B. Order a stat CT of the chest to rule out hemothorax or great vessel injury
- C. Verify the quality of radial pulses
- D. Suture the wound and then discharge home, with close follow-up
- E. Admit to an appropriate consultant for observation.

For the Answer to this Challenge, see page 63.

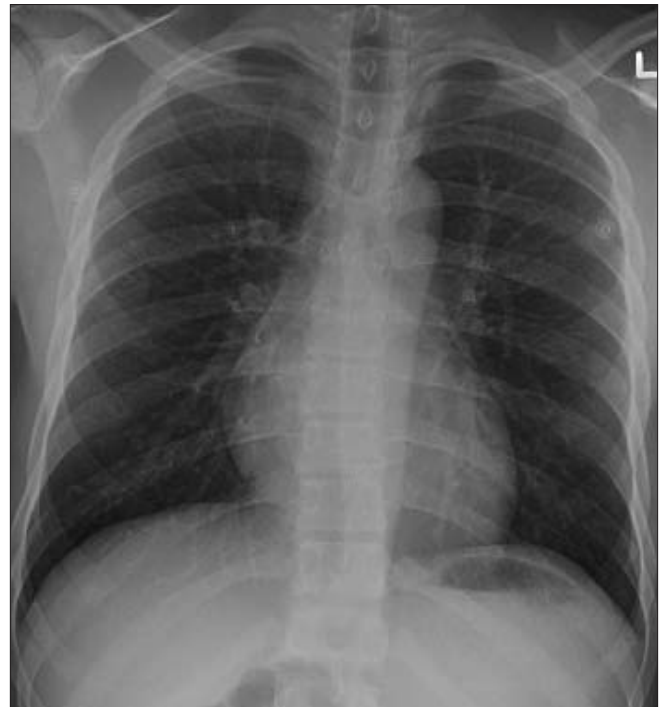


Fig. 1. Upright chest x-ray revealing normal mediastinum and no apparent pneumothorax.

Assistant Professor, Department of Family and Community Medicine, University of Toronto, Toronto, Ont.; Staff physician, Department of Emergency Medicine, Credit Valley Hospital, Mississauga, Ont., and Mount Sinai Hospital, Toronto, Ont.; Director, Canadian Network for International Surgery, Vancouver, BC