

The diagnosis of Othello syndrome associated with SDD was retained.

Our therapeutic strategy has been to put the patient on quetiapine, reduce the doses of levodopa, add a dopamine agonist and involve psychoeducation of the patient and his family. Evolution has been marked by the reduction of delusions of jealousy.

Conclusions: This case reports a rare case of delirium of jealousy induced by the misuse of dopaminergic drugs in a patient with PD in its early form. These complications can have catastrophic consequences for the patient. Researching and recognizing these psychiatric manifestations should help avoid devastating consequences.

Disclosure: No significant relationships.

Keywords: Dopaminergic dysregulation syndrome; Parkinson; Othello syndrome

EPV0308

A case of dissociative identity disorder and attention deficit hyperactivity disorder comorbidity

E.F. Aydın* and T. Koca Laçın

University of Atatürk, Department Of Mental Health And Diseases, Erzurum, Turkey

*Corresponding author.

doi: 10.1192/j.eurpsy.2022.1196

Introduction: Dissociative identity disorder(DID) is characterized by the existence of two or more distinct identities which involve changes in consciousness, emotion, memory, and behavior. It is associated with childhood traumatic experiences and other psychiatric disorders. Comorbidity in DID can lead to complex clinical presentations, poor treatment responses. Thus, it is crucial to identify patients with comorbidity and take them into the treatment plan.

Objectives: We aim to report a case of DID and Attention-Deficit/Hyperactivity Disorder(ADHD) comorbidity.

Methods: A case report is presented alongside a review of the relevant literature regarding “dissociative identity disorder” and “attention deficit hyperactivity disorder”.

Results: We describe the case of a 39-year-old woman with DID, onset at age 25, who had consistently responded poorly to long-term psychotherapy and pharmacological treatment. She presented with anxiety, distinct personality states, alterations in memory, consciousness and behavior problems in functioning, and high Dissociative Experiences Scale(DES) scores. Throughout the interviews, we noticed that she had limited attention, excess movements. After a detailed evaluation, diagnosis of ADHD is established, using the Diagnostic Interview for ADHD(DIVA) and ADHD Self-Reporting Scale(ASRS). Methylphenidate was prescribed in addition to previous medication. Improvement in the severity of both ADHD and DID symptoms was presented with lower scores in DES and ASRS after the introduction of methylphenidate with progressive dose adjusting till 60mg/day.

Conclusions: Although previous studies demonstrated ADHD symptoms are related to dissociation, there is no well-established strategy for this. We believe that this case report provides a better approach to the comorbidity of ADHD and DID.

Disclosure: No significant relationships.

Keywords: disorder comorbidity; Dissociative Identity disorder; Attention Deficit Hyperactivity Disorder; methylphenidate

EPV0310

Dual Diagnosis, Double Trouble

J. Lopes* and R. Freitas

Hospital Espirito Santo, Departamento De Psiquiatria E Saude Mental, Evora, Portugal

*Corresponding author.

doi: 10.1192/j.eurpsy.2022.1197

Introduction: Many individuals with severe mental illness (SMI) have substance use disorder comorbidity. Dual diagnosis makes the approach and management of these patients even more challenging since the lack of improvement in either pathologies can lead to a deterioration of both.

Objectives: To illustrate, through the presentation of two cases, the clinical challenges in managing a patient with dual diagnosis

Methods: Clinical case presentation through retrospective review of clinical notes and non-systematic literature review on this topic

Results: We present the clinical cases of two women diagnosed with Bipolar Disorder and (poly)Substance Use Disorder since adolescence, who have a history of multiple hospitalizations due to mostly manifold symptoms. The complexity of case management is evident, both at the pharmacological level and in psychosocial intervention. This is aggravated by the difficulty in maintaining adherence to the therapeutic project and frequent relapses.

Conclusions: Current evidence points to the beneficial effect of a combined pharmacological and psychosocial approach, which must be comprehensive, individualized and require differentiation at various levels that are difficult to achieve and make the treatment of these situations an even greater challenge.

Using illustrative examples, this review draws attention to the practical difficulties in managing situations where substance use is associated with SMI.

Disclosure: No significant relationships.

Keywords: substance abuse; comorbidity; dual diagnosis

EPV0311

Neuroimaging Correlates of Post-Traumatic Stress Disorder in Traumatic Brain Injury: A Systematic Review of the Literature

A. Esagoff*, D. Stevens, M. Bray, B. Bryant, N. Daneshvari, D. Jung, C. Rodriguez, L. Richey, L. Luna, H. Sair and M. Peters

Johns Hopkins University School of Medicine, Department Of Psychiatry And Behavioral Sciences, Baltimore, United States of America

*Corresponding author.

doi: 10.1192/j.eurpsy.2022.1198

Introduction: Neuroimaging has been a highly utilized technique for studying traumatic brain injury (TBI) and post-traumatic stress disorder (PTSD) independently of one another, however, neuroimaging has increasingly been identified as a useful tool in better understanding TBI-related psychiatric conditions, such as PTSD.

Objectives: To complete a systematic review of the literature examining neuroimaging findings in TBI-related PTSD and to highlight the current literature’s limitations in order to strengthen future research.

Methods: A PRISMA compliant literature search was conducted in PubMed (MEDLINE), PsychINFO, EMBASE, and Scopus databases prior to May of 2019. The initial database query yielded 4388 unique articles, which were narrowed down based on specified inclusion criteria (e.g., clear TBI definition, clinician-diagnosed PTSD, statistically analyzed relationship between neuroimaging and PTSD, quantified time interval between TBI and neuroimaging).

Results: A final cohort of 10 articles met inclusion criteria, comprising the findings of 482 participants with TBI. Key neuroanatomical findings among the included articles suggest that PTSD is associated with significant changes in whole-brain networks of resting state connectivity and disruptions in bilateral frontal and temporal white matter tracts, fronto-limbic pathways, the internal capsule, and the uncinate fasciculus (Figure 1).

Figure 1a: Neuroimaging Findings in TBI-related PTSD.

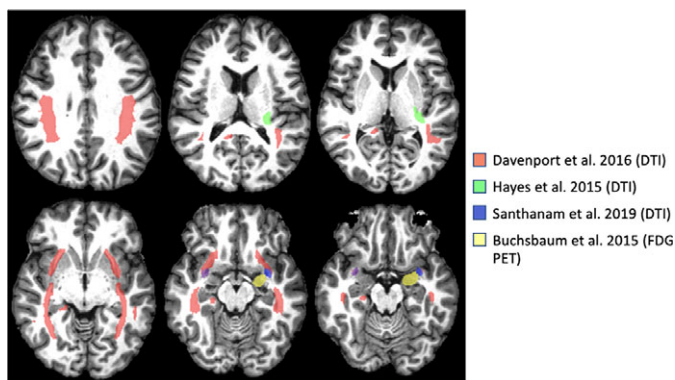
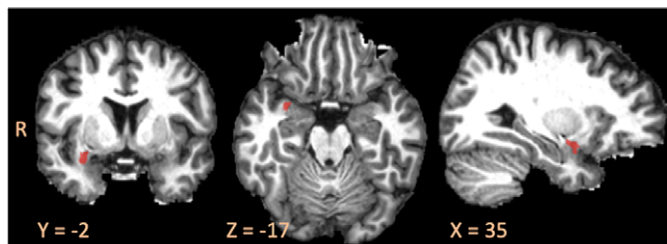


Figure 1b. Replicated Neuroimaging Findings in TBI-related PTSD in the Right Uncinate Fasciculus.



Conclusions: Additional inquiry with attention to specified imaging timing post-injury, consistent TBI definitions, clinician-diagnosed TBI and PTSD, and control groups is crucial to extrapolating discrepancies between primary and TBI-related PTSD. Prospective studies could further differentiate predisposing factors from sequelae of TBI-related PTSD.

Disclosure: No significant relationships.

Keywords: Neuroimaging; Post-traumatic stress disorder; traumatic brain injury

Consultation Liaison Psychiatry and Psychosomatics

EPV0312

An explorative study to assess the psychosocial impact of infertility on female Infertile Patients

B. Ghosh Dastidar

Royal Wolverhampton NHS Trust, University of Birmingham, Psychiatry, WVQP, United Kingdom
doi: 10.1192/j.eurpsy.2022.1199

Introduction: The primary aim of our study was to assess the psychosocial impact of infertility amongst female infertile patients. We selected infertile women visiting the gynaecological OPD of R.G.Kar Medical College and Hospital - one of the busiest and most reputed government hospitals in eastern India. Most of the research on psychological aspects on infertility has been done in the developed rich nations of the world, our study is one of the very few to have been conducted in a developing nation like India.

Objectives: Incidence of depression, psychopathology and anxiety in female infertile patients in comparison to control fertile group. Impairment in quality of life Impact of other variable factors

Methods: Source of data : RGK Medical College, Kolkata, India
Sampling technique : Consecutive Random Sampling
Tools for data collection: Beck's Depression Inventory, Beck's Anxiety Inventory, SF36, SCL 90, Mini International Neuropsychiatric Interview, Self Reporting Questionnaire, Socio Demographic Proforma.

Data Analysis: The data was collected and analyzed by means of descriptive and inferential statistics.

Inferential statistics- Data analyzed by using SPSS. The relationship between continuous and binary explanatory variables with SF36, SCL 90, BDI and BAI scores were assessed using unpaired t test.

Results: Statistical analysis by independent t test shows significant increased levels of depression, anxiety, significant difference in psychopathology and quality of life in the 2 study groups.

Conclusions: Infertility has a significant impact on psychosocial well being of infertile patients, Greater collaboration is required between psychiatrists, psychologists and infertility specialists to assist infertile couples.

Disclosure: No significant relationships.

Keywords: Psychopathology; Depression; Anxiety; Infertility

EPV0313

Building bridges between body and mind: liaison psychiatry

S. Bravo Herrero^{1*}, I. Moreno Alonso², M.J. Sánchez Artero¹ and A.M. Matas Ochoa¹

¹Hospital Universitario Infanta Leonor, Liaison Psychiatry, Madrid, Spain and ²Hospital Universitario Infanta Leonor, Home Treatment Team, Madrid, Spain

*Corresponding author.

doi: 10.1192/j.eurpsy.2022.1200

Introduction: As liaison psychiatrists, it is very important to maintain a good relationship with other medical specialties in order