

Neuroimaging Highlight

Editor: David Pelz

Multifocal Cerebellar Liponeurocytoma

Submitted by: Navid Khezri, Todd Mainprize, Nicolas Phan, Julia Keith, Juan Bilbao, Richard I. Aviv, May Tsao, Sean P. Symons

Can J Neurol Sci. 2013; 40: 870-872

A 54-year-old female presented with a two year history of progressive headaches and upper neck pain. The headaches were worse with coughing and bending. Neurological examination was unremarkable including a normal cranial nerve examination. There was no papilloedema. A computed tomogram (CT) demonstrated a midline, posterior fossa, partly fatty, partly solid mass (Figure 1). Magnetic resonance imaging (MRI) demonstrated a mixed fatty, solid mass arising from the fourth ventricle and extending downward below the foramen magnum to the C1 level (Figure 2). The solid portions demonstrated enhancement. In addition, in the lateral right cerebellar hemisphere, there was a second, separate, solid, enhancing mass without any connection to the larger central lesion. A subtotal resection of the tumor was achieved through a suboccipital craniectomy.

The tumor had a biphasic pathologic appearance, comprised of mature adipose tissue and densely cellular neurocytic neoplasm. In some areas, these two morphologies were juxtaposed (Figure 3A) and in other areas they were

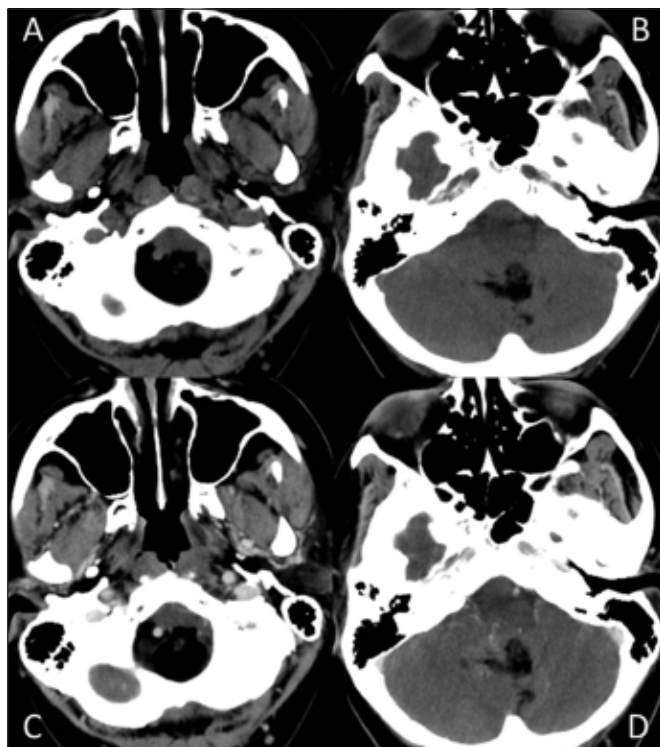


Figure 1: (A,B) Axial CT images of the brain demonstrating a mixed fatty / solid midline posterior fossa mass. (C,D) Following iodinated intravenous contrast, the solid portions of the mass enhance.

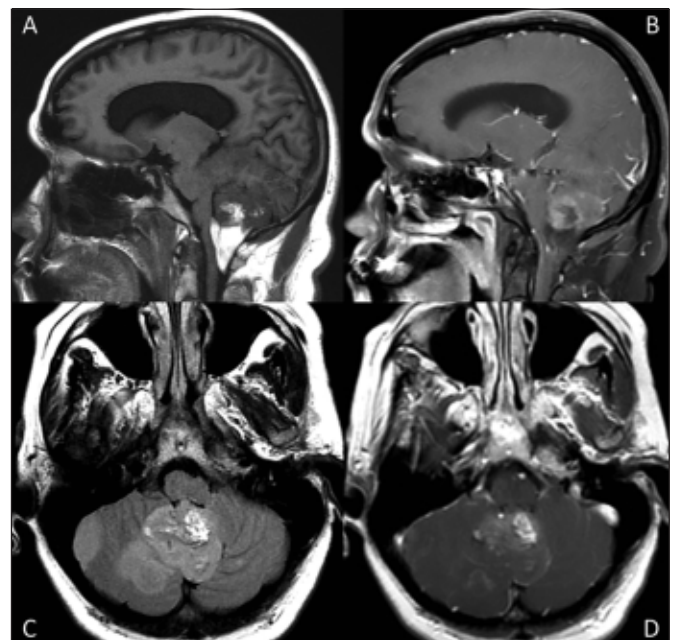


Figure 2: (A) Sagittal T1-weighted MR image of the brain demonstrates a midline mass with fatty (hyperintense) and solid (hypointense) components. (B) Sagittal T1-weighted MR image with gadolinium contrast and fat saturation. The fatty portions of the mass are now hypointense. The solid portions demonstrate enhancement. (C) Axial FLAIR MR image demonstrates the hyperintense midline mass as well as a second separate FLAIR hyperintense right lateral cerebellar mass. (D) Axial T1-weighted image with gadolinium demonstrates enhancement of the solid portions of the midline mass as well as faint enhancement of the second separate right lateral cerebellar mass.

From the Division of Neuroradiology (NK, RIA, SPS), Division of Neurosurgery (TM, NP), Department of Pathology (JK, JB), Department of Radiation Oncology (MT), Department of Otolaryngology - Head & Neck Surgery (SPS), University of Toronto, Toronto, Ontario, Canada.

RECEIVED JANUARY 21, 2013. FINAL REVISIONS SUBMITTED JUNE 18, 2013.
Correspondence to: Sean Symons, Division of Neuroradiology, Department of Medical Imaging, Sunnybrook Health Sciences Centre, 2075 Bayview Avenue, AG31D, Toronto, Ontario, M4N 3M5, Canada. Email: sean.symons@sunnybrook.ca.

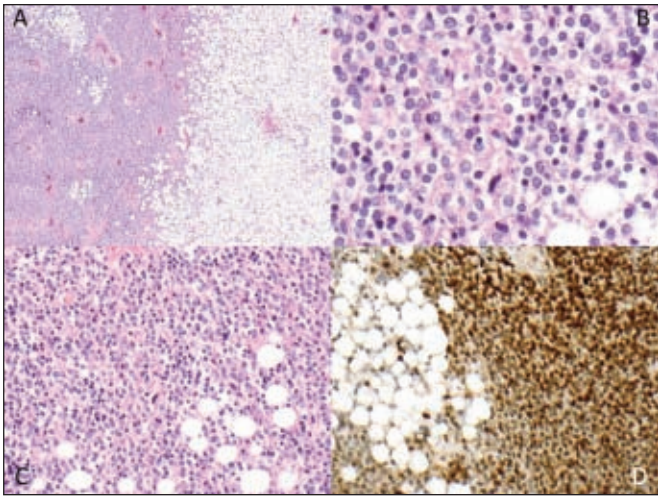


Figure 3: (A) H&E stained section (magnification 4x) showing a biphasic tumour, comprised of mature adipose tissue and densely cellular neurocytic neoplasm. In some areas these two morphologies were juxtaposed. (B) H&E stained section (magnification 40x) of a neurocytic portion of the tumour showing round, monomorphous cells with focal perinuclear cytoplasmic clearing. (C) H&E stained section (magnification 20x) showing intermingling of the adipose tissue with the neurocytic tumour. (D) The neurocytic cells strongly expressed neuronal immunohistochemical markers including NeuN (magnification 20x).

intermingled (Figure 3C). The adipose tissue had a mature appearance without lipoblasts, though the adipocytes were quite small. The solid neurocytic tumor was densely cellular with a neuropil background, and the lesional cells had round monomorphous nuclei, finely stippled chromatin, and focal perinuclear clearing (Figure 3B). There were no malignant features such as mitoses, endothelial proliferation, or necrosis. The lesional cells strongly expressed neuronal markers such as synaptophysin and NeuN (Figure 3D). They were predominantly negative for glial fibrillary acidic protein, and the Ki67 proliferative index was low.

No adjuvant therapy was initiated and the patient was followed with serial imaging. An MRI scan performed two years after the initial surgery revealed enlargement of one of the residual nodules. This was resected. Two years after this, there was a second recurrence in the surgical bed as well as a new left superior cerebellum tumor (Figure 4). All of the recurrences consisted of solid, non-fatty tumor. After the second recurrence, radiation was offered but declined by the patient.

DISCUSSION

Cerebellar liponeurocytomas are rare, slow-growing tumors first reported in 1978¹. The pathological features resembling medulloblastoma in addition to lipidized cells originally resulted in a variety of names, including 'lipomatous medulloblastoma'²⁻⁴, 'lipidized medulloblastoma'^{5,6}, 'medullocytoma'⁶, 'neuro-lipocytoma'⁷, and 'lipomatous glioneurocytoma'⁸. However, due to the tumor's different prognosis, epidemiology, and clinical presentation, the World Health Organization in 2000 defined cerebellar liponeurocytoma as a distinct lesion from

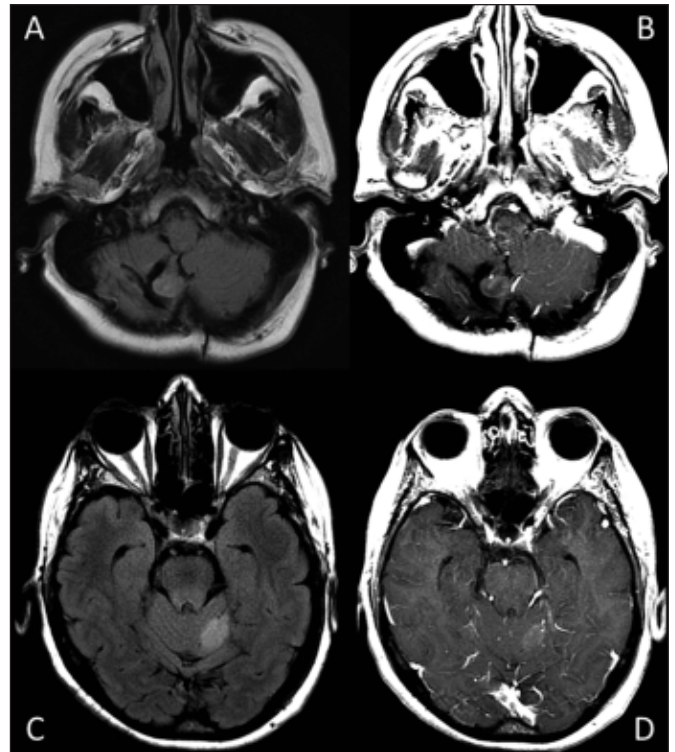


Figure 4: (A) Axial FLAIR image demonstrates recurrent FLAIR hyperintense tumour nodule in the resection bed. (B) Axial T1-weighted image with gadolinium contrast demonstrates enhancement of the nodule. (C) Axial FLAIR image demonstrates a new hyperintense left superior cerebellar mass. (D) Axial T1-weighted image with gadolinium contrast demonstrates enhancement of the new left superior cerebellar mass.

medulloblastoma.⁹ It was first classified as grade I based on a perceived indolent behavior, but upgraded to II in 2007 due to higher documented recurrence rates.^{10,11}

It is important to differentiate between a liponeurocytoma and a medulloblastoma. Liponeurocytoma present at an older age (average 49), is treated with surgery, the role of chemoradiation is controversial, and has an excellent prognosis.¹² Medulloblastoma present at a younger age (average age for adult medulloblastomas is 28), is treated by surgery plus chemoradiation, and has a poorer prognosis. Giordana et al described the presence of lipidized cells in 6 of 78 adult medulloblastomas, and in 8 of 44 childhood medulloblastomas.¹³ Six of these cases were heavily lipidized. These tumors did not act like liponeurocytomas in terms of clinical outcomes and pathological features.

It is also important to note that supratentorial cases of liponeurocytoma have now been described.¹⁴

We have described a case of a cerebellar liponeurocytoma with characteristic radiological and pathological findings, except for a unique, separate satellite lesion at presentation. To our knowledge, a multifocal liponeurocytoma has not been previously reported. The tumor is usually surgically resected. Recurrences are not uncommon, up to 40% in one study.^{9,10} The role of radiation is uncertain.

REFERENCES

1. Bechtel JT, Patton JM, Takei Y. Mixed mesenchymal and neuroectodermal tumour of the cerebellum. *Acta Neuropathol.* 1978 41(3):261-3.
2. Budka H, Chimelli L. Lipomatous medulloblastoma in adults: a new tumor type with possible favorable prognosis. *Hum Pathol.* 1994;25(7):730-1.
3. Chimelli L, Hahn MD, Budka H. Lipomatous differentiation in a medulloblastoma. *Acta Neuropathol.* 1991;81(4):471-3.
4. Soyomezoglu F, Soffer D, Onol B, Schwechhimer K, Kleihues P. Lipomatous medulloblastoma in adults. A distinct clinicopathological entity. *Am J Surg Pathol.* 1996;20:413-8.
5. Davis DG, Wilson D, Schmitz M, Markesbery WR. Lipidized medulloblastoma in adults. *Hum Pathol.* 1993;24(9):990-5.
6. Giangaspero F, Cenacchi G, Roncaroli F, et al. Medulloctoma (lipidized medulloblastoma). A cerebellar neoplasm of adults with favorable prognosis. *Am J Surg Pathol.* 1996;20(6):656-64.
7. Ellison DW, Zygmunt SC, Weller RO. Neurocytoma/lipoma (neurolipocytoma) of the cerebellum. *Neuropathol Appl Neurobiol.* 1993;19(1):95-8.
8. Alleyne CH Jr, Hunter S, Olson JJ, Barrow DL. Lipomatous glioneurocytoma of the posterior fossa with divergent differentiation: case report. *Neurosurgery.* 1998; 42(3):639-43.
9. Kleihues P, Chimelli L, Giangaspero E. Cerebellar liponeurocytoma. In: Kleihues P, Cavenee WK, editors. *World Health Organization classification of brain tumors: pathology and genetics of tumours of the nervous system*, third edition. Lyon: International Agency for Research on Cancer; 2000. p. 110-11.
10. Kleihues P, Chimelli L, Giangaspero F, Ohgaki H. Cerebellar liponeurocytoma. In: Louis DN, Ohgaki H, Wiestler OD, Cavenee WK, editors. *World Health Organization classification of tumours of the central nervous system*, fourth edition. Lyon: International Agency for Research on Cancer; 2007. p. 110-12.
11. Nishimoto T, Kaya B. Cerebellar liponeurocytoma. *Arch Pathol Lab Med.* 2012;136(8):965-9.
12. Patel B, Fallah A, Provias J, Jha NK. Cerebellar liponeurocytoma. *Can J Surg.* 2009;52(4): E117-19.
13. Giordana MT, Schiffer P, Boghi A, Buoncristiani P, Benech F. Medulloblastoma with lipidized cells versus lipomatous medulloblastoma. *Clin Neuropathol.* 2000; 19(6):273-7.
14. Chakraborti S, Mahadevan A, Govindan A, et al. Supratentorial and cerebellar liponeurocytomas: report of four cases with review of literature. *J Neurooncol.* 2011;103(1):121-7.